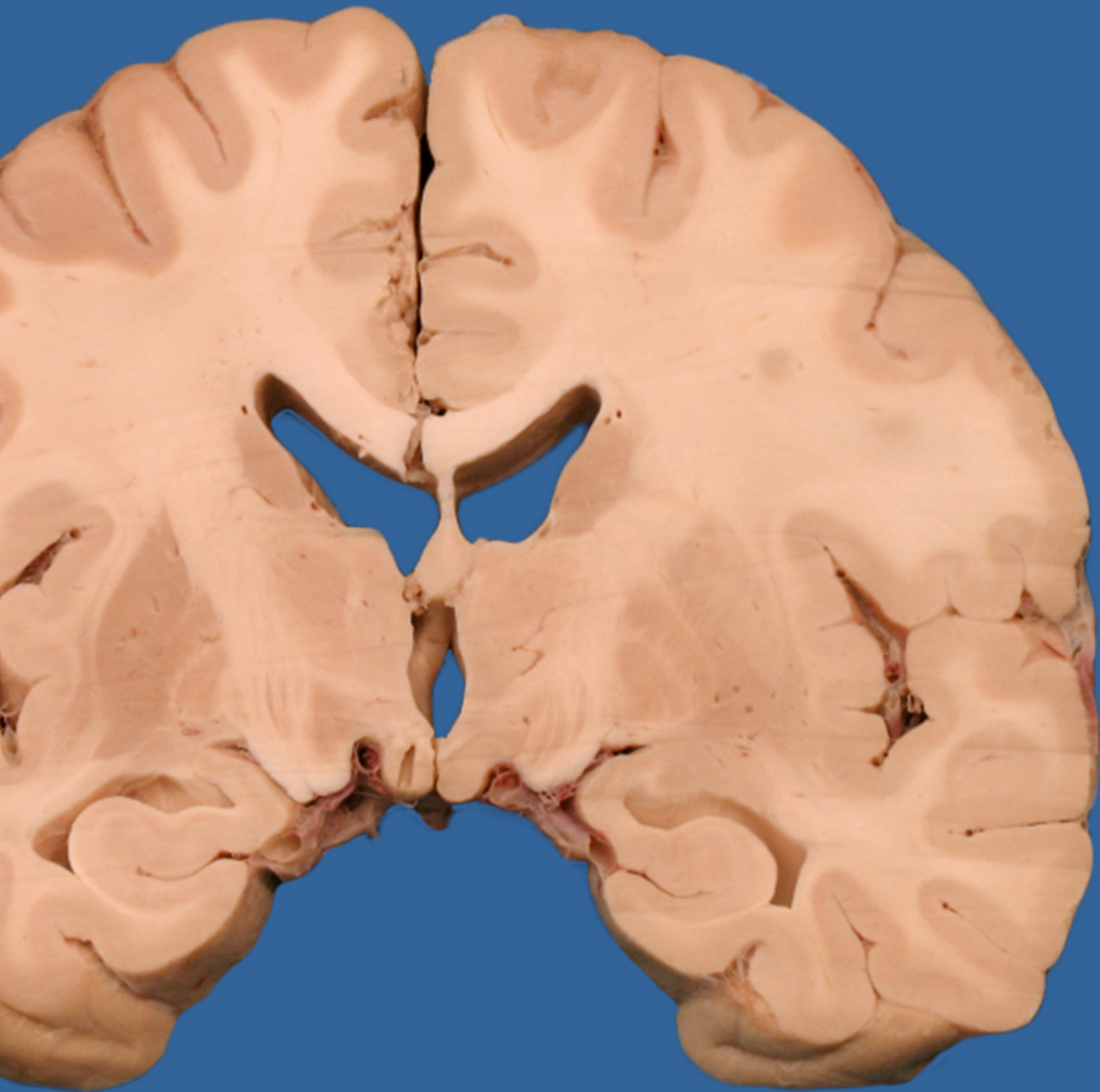


# Chapter 2:

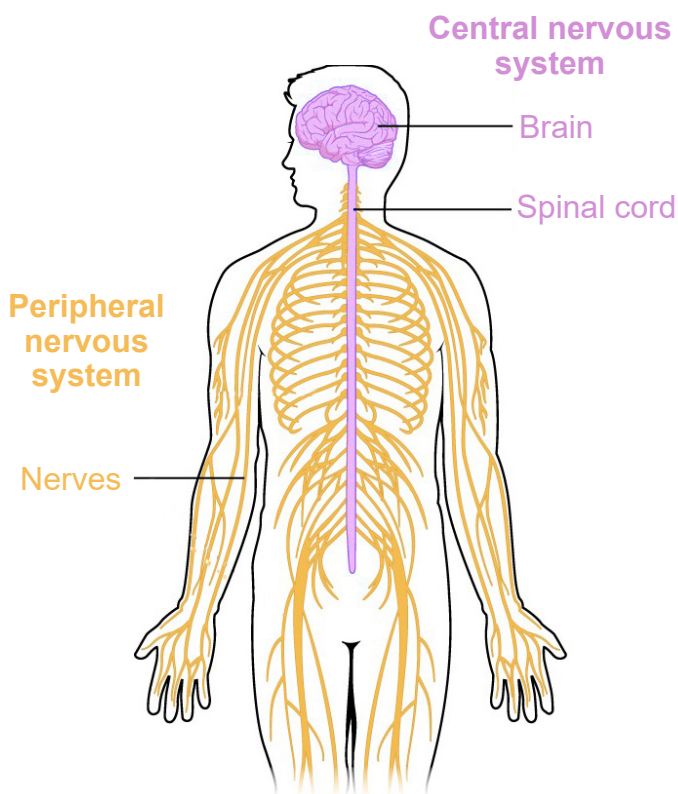
## Anatomy of the Nervous System



To physically take something apart is a great way to learn about the relationship between structure and function. Engineers and electricians use schematics to help them figure out what parts connect to where, and architects may use blueprints to aid them in the creation of a building. You can learn a lot about a system by understanding the function of the individual components and how they interact with one another. The whole is often greater than the sum of their parts, and a failure of one part to perform its duty can have wide reaching consequences.

The nervous system is one of the most complex systems that we know of. Parts of this system malfunction frequently, and the results

**Figure 2.1** Anatomical structures of the CNS and the PNS.

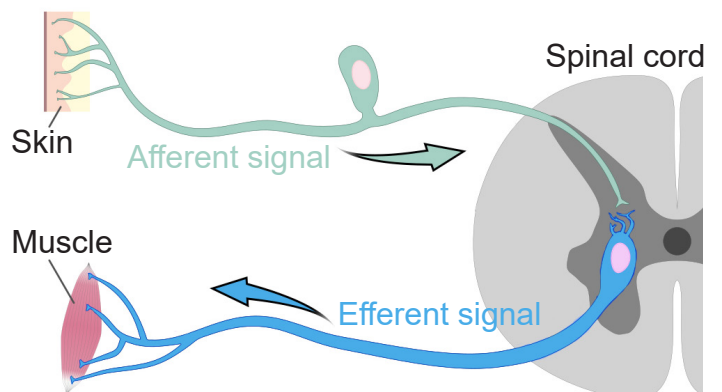


are a wide range of neurological disorders that affect humans, from injury to genetic disorders.

The gross anatomy of the nervous system is an important foundation to the studies of other aspects of neuroscience. This chapter covers some of the major anatomical structures in the nervous system, starting with the brain, working down the spinal cord, all the way out to non-nervous tissue. The end of this chapter will also cover the many support structures that allow the nervous system to carry out their jobs.

Broadly speaking, the nervous system can be divided into two main categories: The **central nervous system (CNS)** and the **peripheral nervous system (PNS)**. Simply put, the CNS is the brain and spinal cord, while the PNS is all the other nerve cells in the body. The two systems are not isolated from each other; information passes rapidly between the PNS and the CNS, and vice versa. When a signal that originates in the PNS moves to the CNS, we sometimes say that the signal is *incoming* or *ascending*, while the CNS to PNS direction is *outgoing* or *descending*. Information that arrives into the CNS is also

**Figure 2.2** Afferent versus efferent signals.



called an **afferent** signal, while information leaving the CNS is an **efferent** signal. These two terms are frequently confused, but you can use the knowledge of other words that start with “e” to remember that an “exit” or an “escape” is

something that moves away. Alternatively, an efferent signal is something that has an *effect* on the outside world, while an afferent signal *affects* the person.

---

## Chapter 2 outline

---

- 2.1 Central nervous system (CNS)
- 2.2 Peripheral nervous system (PNS)
- 2.3 Support structures of the nervous system

---

### 2.1 Central nervous system (CNS)

---

Anatomically, the CNS consists of two organs, the brain and the spinal cord.

The brain is the main organ where movement originates, where thoughts and plans develop, and where consciousness is housed. The brain is what pushes us to act on our drives and desires, where language begins, and where memories are stored. At 160 mm ( ~6 in) long

and 90 mm tall ( ~3.5 in), it has a total volume of about 1400 cubic centimeters and would fill about a third of a gallon. The intact adult brain weighs about 1.5 kg (3 pounds), which is barely 2% of total body weight. Despite this relatively small size, it is extremely power hungry, and uses up about one-fifth of the body’s total energy expenditure.

### Anatomical language of the brain

When talking about parts of the brain, it is helpful to have a set of words that can describe the location of various anatomical structures unambiguously. Think of the following three pairs of anatomical words as the “north, east, south, west” of the brain.

Consider a person who is facing sideways. Here, we’d like to use language that can describe anatomical structures that are along the “front of the head” to the “back of the head” axis. Parts of the brain that are more forward are called **rostral**, which comes from the Latin word meaning beak. To describe structures towards the back part of the brain, we use **caudal**, the opposite of rostral. Another pair of words that describes this same

directional axis is **anterior** and **posterior**: ante-meaning “before” and post- meaning “after”. Often, rostral and anterior are used interchangeably, as are caudal and posterior.

Another axis that should be considered is the top-to-bottom direction. Brain structures that are above, or closer to the top of the head, are described as being **dorsal**, while the structures that are below are **ventral**. As before, you may see another pair of words that share the same meaning. Sometimes, **superior** is used to describe a structure on top, while **inferior** is used to describe a structure below.

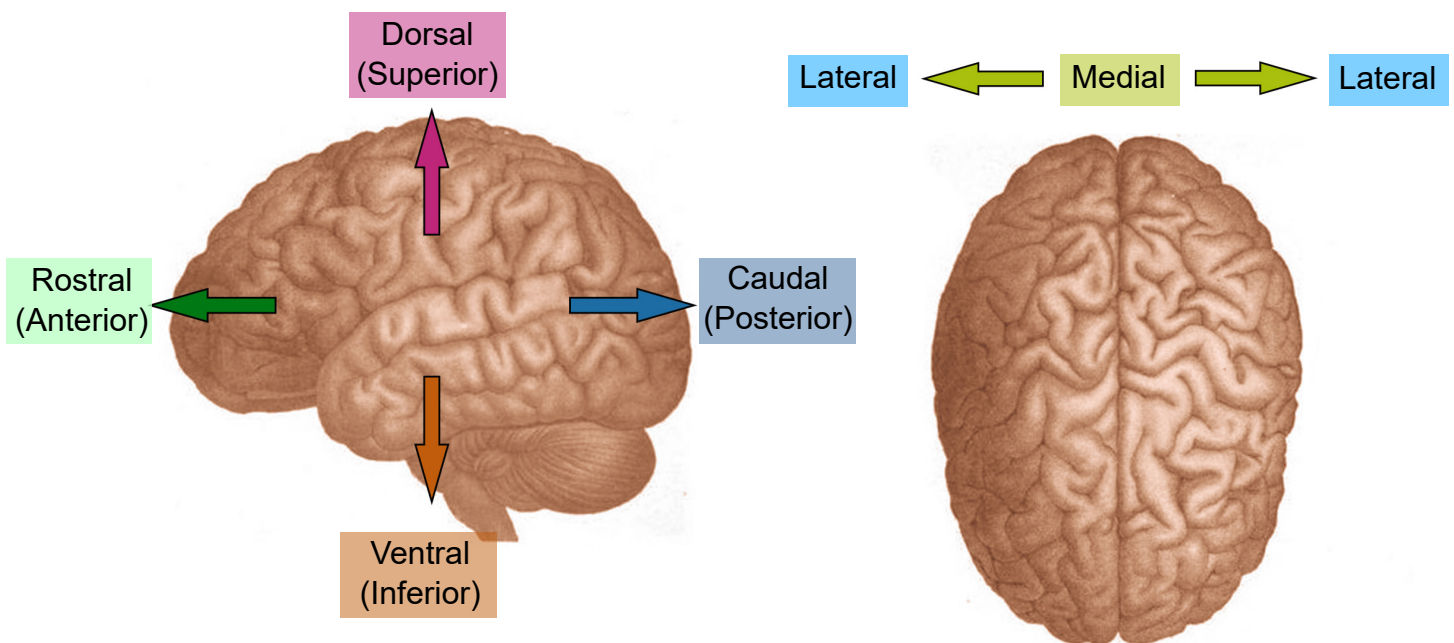
Now, imagine that the person has turned to face towards you. The third axis can be

demonstrated seen in this orientation. Brain structures that are closer to the center of the brain are described as being **medial**, while structures that are closer to the sides of the brain are **lateral**.

Neuroanatomists use these words to describe the relationship of one structure to another. For example, in Fig 2.7 which shows the four lobes of the brain, the frontal lobe is anterior or rostral to the parietal lobe, and the parietal lobe

is dorsal to the temporal lobe. These anatomical words can also be combined to subdivide complex brain regions. The thalamus has many small subsections, such as the dorsomedial nucleus or the ventropostero-lateral nucleus. Naming structures with this anatomical language is useful in identifying where they are located in a brain scan or autopsy, but these words tell us nothing about function.

**Figure 2.3** A cartoon illustration of the brain showing anatomical language.



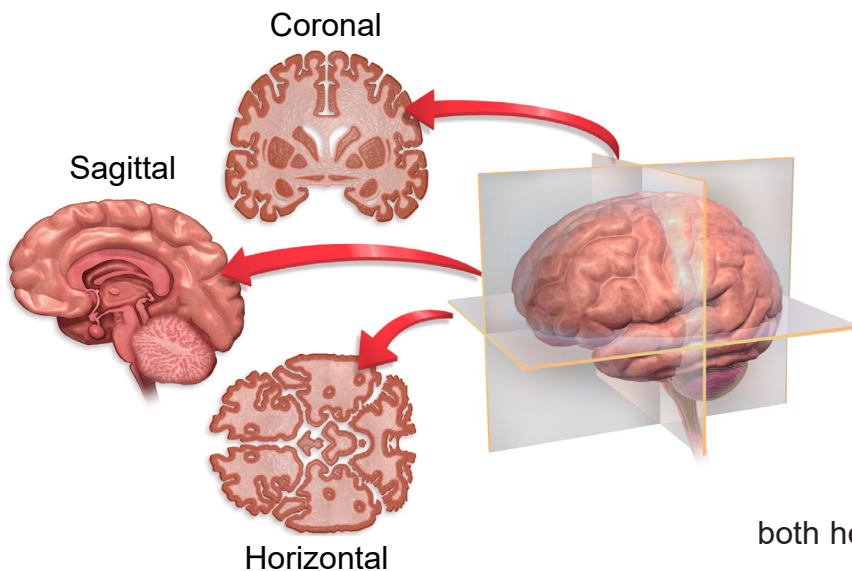
## Visualizing the brain

As a three dimensional structure, the brain can be sectioned for visualization or analysis in several ways. Here, we will describe the three main orientations, each at right angles to the others.

One projection of the brain is called a **coronal** slice. Imagine that you were looking at a brain of a person who was looking to the left. If the brain was cut into several sections vertically, slicing from anterior to posterior, the brain would be cut into coronal slices. “Corona” comes from the Latin word for crown, since looking at the brain cut into slices parallel to a crown would be

a coronal section.

Another way to image the brain is called a **horizontal** projection. In a horizontal slice, cuts are made along the dorsal-ventral direction, from the top of the brain to the bottom. Given that the person is standing up, horizontal slices are parallel to the plane of the ground. Another way to think of the horizontal plane is through brain imaging techniques where a person moves headfirst into a scanner. Here, the machines are capturing horizontal images where each progressive image is a snapshot of the brain slightly more ventral than the last.



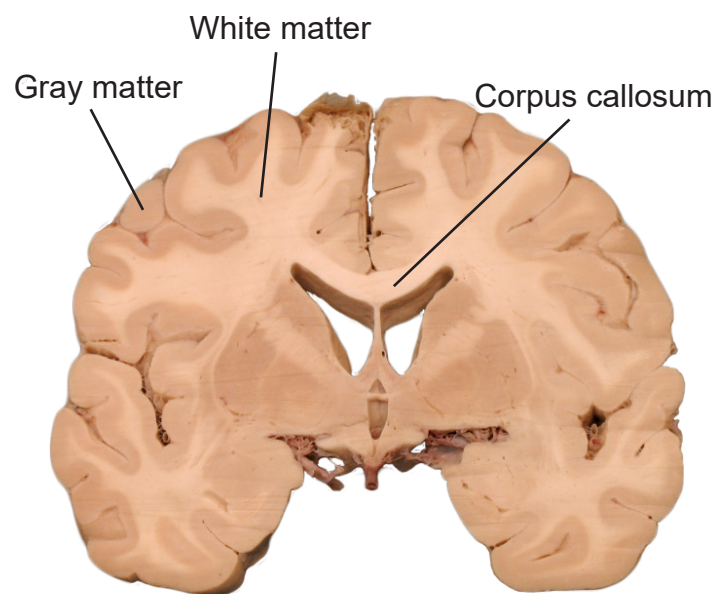
**Figure 2.4** Cross sections used for visualizing the three orientations of the brain.

The third and last direction is a **sagittal** slice. The sagittal section takes cuts parallel to the midline, slicing in the medial / lateral plane. If a person was facing you, and brain sections were taken across from left to right, these would be sagittal sections. Notably, because the sagittal section only samples from one hemisphere of the brain at a time, sagittal slices are never symmetrical. The word sagittal comes from the Latin word meaning arrow, like the zodiac sign Sagittarius (If you were an archer drawing back a bow and arrow, a sagittal slice would be parallel to that plane).

In a sliced section of the brain, you might notice that brain tissue has different colored areas. Some brain tissue is pale and almost white, and these areas are described as **white matter**. Generally, white matter represents pathways of communication. For neurons to send signals rapidly, the cells can be modified in a way that adds several layers of fatty lipids called **myelin**. This modification causes light to

reflect, causing it to appear white to the eye (think of the strips of fat that you might see in a steak). Other sections of brain tissue have a darker pink / gray color, appropriately called **gray matter**. These areas are usually dense with cell bodies.

The brain has two very similar halves, the left and right hemisphere. Oftentimes, in the neurotypical individual, information passes between both hemispheres rapidly: what one hemisphere senses or learns, so does the other hemisphere. It is the white matter tracts that allow for this transfer of information. When a white matter pathway crosses from one hemisphere to another, we call it a decussation. In coronal or horizontal brain slices, you may be able to observe the main white matter tract that allows for the passage of information between the two hemispheres, called the **corpus callosum**.



**Figure 2.5** Coronal brain section showing examples of white matter, gray matter, and the **corpus callosum**, the major communication tract between the left and right hemispheres.

# Brain structures through development

The brain is often divided into five groups based on their developmental origin. When the embryo first starts to form, cells are classified into three main germ layers: the ectoderm, mesoderm, and endoderm. Of the three, the ectoderm eventually develops into the nervous system. The ectoderm layer folds into itself, and after merging at the surface, creates the **neural tube**. This neural tube forms during the third to fourth week of gestation. The cells of the neural tube will eventually become the components of the CNS.

Early in development, the neural tube has three distinct compartments. At this time, the undeveloped nervous system is appropriately called the “three-vesicle stage.” One week later, parts of this progenitor nervous system divide; this becomes the “five-vesicle stage.” The names of the five vesicles can be used to describe either the stages through development, or a grouping of structures that eventually form in adulthood. From posterior to anterior, they are:

## 1. Rhombencephalon, or hindbrain.

Evolutionarily speaking, the rhombencephalon represents the oldest part of the CNS. These structures likely evolved some 570 million years ago. As these structures develop into the five-vesicle stage, they become subdivided into two regions:

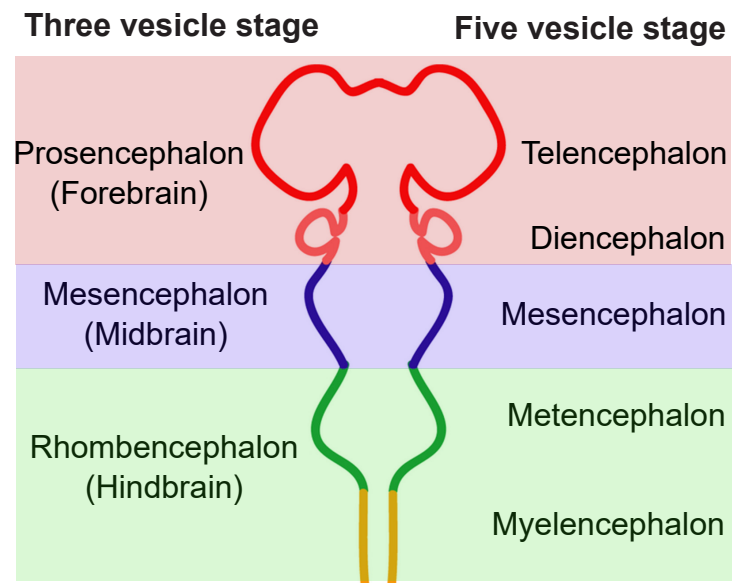
**a. Myelencephalon.** The myelencephalon develops into the **medulla oblongata**, a structure that is found at the posterior end of the brain stem. The medulla contains many clumps of neurons that are responsible for functions that an organism carries out unconsciously, such as breathing or changes in heart rate and blood pressure. It also contains areas that can detect toxins in the blood that come from dietary sources,

triggering vomiting.

**b. Metencephalon.** The metencephalon develops into two structures, the **pons** and **cerebellum**. The pons, like the medulla, helps us perform involuntary functions like breathing. It also contains several areas that help us hear sounds and taste foods. The cerebellum, or “little brain”, is best known as a structure that enables motor control functions, such as balance, coordination, posture, and learning physical actions.

**2. Mesencephalon, or midbrain.** The midbrain structures do not change much from the three-vesicle stage to the five-vesicle stage. There are many structures in the midbrain, and they can perform a wide variety of functions. For example, the periaqueductal gray allows us to respond to painful stimuli, the red nucleus and substantia nigra coordinate complex movements, the tectum allows us to respond to incoming visual stimuli, and the ventral tegmental area is important for the processing of reward and motivation.

**Figure 2.6** The future structures of the developing nervous system.



**3. Prosencephalon, or forebrain.** The prosencephalon eventually develops into the “higher order” brain regions, including the cerebral cortex. Most of the time, when you see an image of an intact brain from the side or the top, the structures that are visible to you are the forebrain structures.

**a. Diencephalon.** The diencephalon contains a few major structures. The **thalamus** is often referred to as a “relay station” in the brain, since almost every sensory modality (sight, taste, touch, hearing, and more) passes information through the thalamus. The **hypothalamus** is also within the diencephalon, and this structure serves as a communication route to the body’s endocrine system. Neural signals originating in the hypothalamus have the capability to influence the chemistry and function of the entire body.

**b. Telencephalon.** Structures of the telencephalon are the basal ganglia and cerebral cortex. The **basal ganglia** are made up of a series of brain structures that are used for such behaviors as motor and habit learning, emotional

processing, and action selection. The **cerebral cortex** makes up the outermost layer of the brain: the word cortex itself comes from the word meaning “bark,” the outer layer of a tree. Here, the brain processes behaviors such as attention, memory, and language.

It may be useful to think of brain structures as roughly being organized in a phylogenetic “timeline”. The more basic features of a creature are generally controlled by posterior brain structures, and the more complex functions are carried out by structures towards the anterior end of the brain. For example, the brain stem of the hindbrain contains networks of cells for basic survival, such as respiration and simple locomotion. Next, the midbrain is important for motivation and more coordinated movements. And finally, the forebrain carries out the highest order functions, such as personality, intentional inhibition of actions, and planning out long term actions. All of the structures work together simultaneously to produce the whole range of animal activities.

## Major lobes of the cortex

Most of what we see when we imagine the brain is **cortex**, the bumpy outer surface that is made up of raised ridges (**gyri**, singular **gyrus**) and grooved indentations (**sulci**, singular **sulcus**; sometimes also called a **fissure**). Although each gyrus and sulcus has a name that either identifies its function or location, there are only three sulci that we will introduce here to help orient us around the neuroanatomical features of the cortex. The **longitudinal fissure** is the most obvious fissure in the brain. It divides the two hemispheres, running along the anterior-posterior axis, visible from a dorsal view of the brain. If you were to cut along the longitudinal fissure completely, you would get two symmetrical portions of brain, the

left and right hemispheres. The **central sulcus** is a large fissure that starts at the dorsal part of the brain at about the halfway point on the anterior-posterior axis. In a sagittal view, the central sulcus runs ventrally about half the length of the brain. The other groove worth noting is the **lateral fissure**. This one runs roughly along the anterior to posterior direction, and curves gently dorsally. Again in a sagittal view, it is roughly seen in the middle third of the brain in the anterior-posterior axis.

The cortex is roughly divided into 4 major lobes, which are named after the bones of the skull that surround each section of brain. The lobes are paired, meaning that the whole brain contains

two of each, a left and a right. In general, the structures are roughly symmetrical. The four lobes of the cortex and their functions, approximately from posterior to anterior, are:

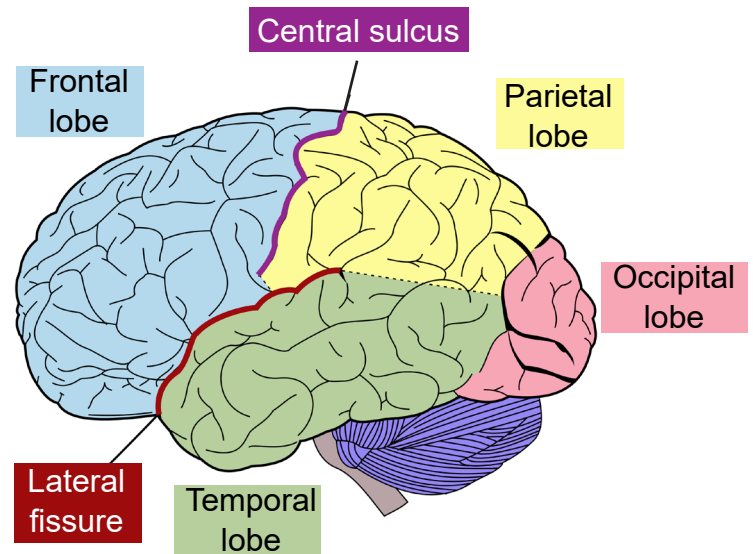
**1. Occipital lobe.** The occipital lobe is the posterior most section of the brain. Anatomically, there is not an obvious border that separates the occipital lobe from adjacent areas of the cortex. The occipital lobe is the smallest of the four lobes.

The main function of the occipital lobe is for processing of visual stimuli. Our eyes are capable of capturing light and converting that light into signals. The **primary visual cortex** of the occipital lobe, also called **V1**, interprets those signals into a representation of the visual world. Other vision-related stimuli, such as objects in motion, object orientation, and color are also processed by neurons in the occipital lobe.

**2. Parietal lobe.** The parietal lobe is in the dorsal aspect of the brain, and immediately anterior to the occipital lobe. The anterior-most (front) end of the parietal lobe is bordered by the central sulcus, and the ventral border is the lateral fissure.

The sense of touch is complex. With our skin, we are able to detect light touch, temperature, pain, vibration, and many other modalities. This ability to sense different tactile properties of things in the world around us with our body is one of the major functions of the parietal lobe. This function is carried out by the **primary somatosensory cortex**, or **S1** (soma-referring to the body). Another closely related sense, proprioception, the ability to identify where parts of your body are located, is also processed by neurons of the parietal lobe.

**3. Temporal lobe.** The temporal lobe is the ventral-most lobe of the brain, and the lateral fissure marks its dorsal border. It is anterior to



**Figure 2.7** Lobes of the telencephalon and two of the major sulci.

the occipital lobe. It is the lobe of the brain that is immediately behind the temple, the structure on the lateral aspect of the skull. The name comes from the Latin word meaning time: the passage of time in adults is often marked by graying hair, and these gray hairs may first appear at the temples.

The auditory system allows our brain to interpret sound waves. We can distinguish between voices talking, instruments playing, and dogs barking. This is possible because of a population of cells located in the temporal lobe called the **primary auditory cortex**, or **A1**.

The ability to remember important facts depends on memory-related processes. These functions are carried out in part by a brain structure called the **hippocampus**, which is buried medially and ventrally in the temporal lobe.

The temporal lobe also houses some structures that are important for language. Patients with injuries in parts of the temporal lobe may experience deficits in the comprehension of language, while different injuries lead to a deficit in the production of language.



**4. Frontal lobe.** The frontal lobe is the anterior most part of the brain. The posterior border of the frontal lobe is the lateral sulcus. Among mammals, it is the largest of the four lobes.

The frontal lobe contains the **primary motor cortex**, or **M1**, which is directly anterior to the central sulcus. M1 contains neurons that control movement of the body. For example, if you were to activate the dorsal most part of M1 in

a person, you would see motor activity in the leg.

The frontal lobe also carries out the “higher order” functions of the brain. Our personality is influenced by the frontal lobe - an injury to these brain structures can result in a radical change in a person’s behavior. Frontal lobe allows us to do mental math, to hold a string of letters in our head to be repeated backward, and to suppress socially unacceptable actions.

### Clinical connection: Phineas Gage

The mid-1800s saw an expansion of industry in the United States. The most reliable and quickest way to move goods and people was with the railways that were starting to zig-zag across the growing country. The factor slowing down railway expansion was terrain: land had to be relatively flat for the tracks to be laid down. Terraforming mountains was a dangerous ordeal, and in the years before TNT, a relatively safe explosive was developed, work accidents were a risk that these demolition workers faced.

Phineas Gage was one of those workers. In the green mountain hills of Vermont, Gage was putting explosive powder into a crack in a mountain to clear land for a new railway. As Gage packed the explosive using a three-foot-long metal rod, a spark accidentally ignited the blast prematurely, causing the tamping iron to rocket cleanly through Gage’s skull.

Miraculously, Gage survived the blast. Within a month, he had made an almost complete recovery. Gage was talking excitedly with his doctors, he was eating voraciously, and even reported experiencing no pain. While the doctors noticed that his entire frontal lobe had been destroyed, it was his friends who noticed the dramatic change in his personality: whereas he was once a friendly man, adored and respected by his coworkers, the new Gage was irreverent, generally unlikable, and prone to using profanity at the most inappropriate times. The pre-injury Gage was a shrewd businessman who followed through with his plans, but Gage now was unreliable and at times, acted almost animalistically. Because of the injuries to his frontal lobe, his friends described him as being “no longer Gage.”



**Figure 2.8** Phineas Gage with the tamping rod (left) and a drawing of the injury (right).

## Spinal cord

It is sometimes easy to think of neuroscience as a focused study of the brain: How does activity of the brain contribute to behavior? In what ways does the brain change in disease? Why do the cells of the brain behave the way they do?

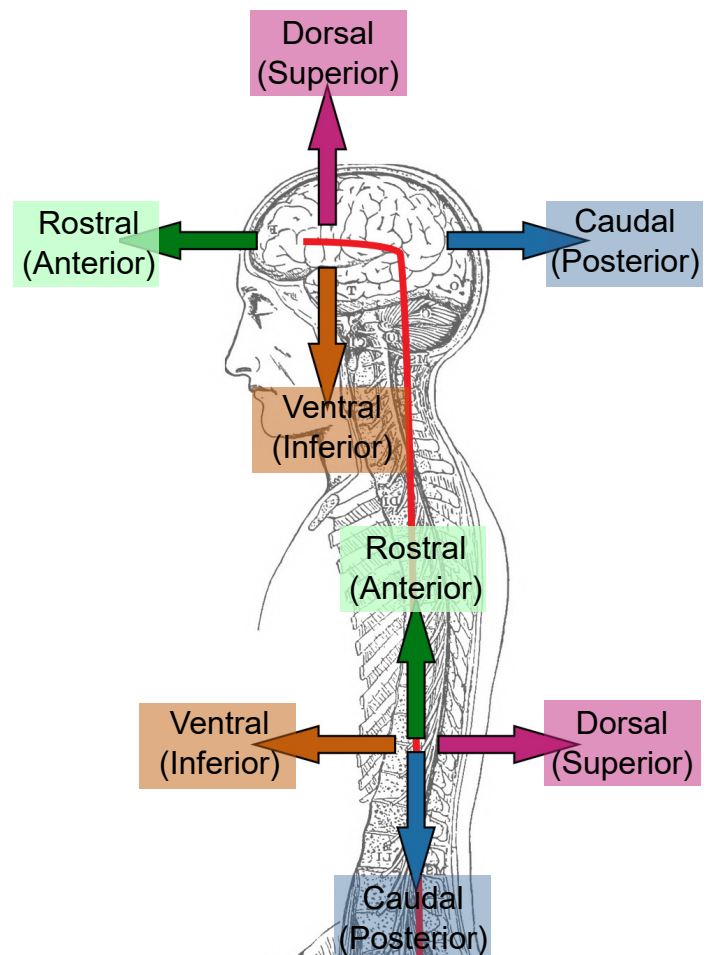
The truth is there are many parts of the body that also fall under the broad study of neuroscience. For example, the automatic knee-jerk reflex that a clinician examines when they tap on your patellar tendon is a test of the nervous system. The reflex is driven by sensory neurons that detect muscle stretch, motor neurons that cause the kicking response, and interneurons that prevent the opposing muscle from acting. We have neural circuits that provoke changes in the activity of our internal organs, from the beating of our heart to the digestion of food, and the study of these systems is certainly part of neuroscience as well.

Moving posterior from the brainstem is the other organ of the central nervous system, a long, thin structure of nervous tissue called the **spinal cord**. It functions to carry information both upwards towards the brain, and downwards towards the body's other organs and muscles. It can also process sensations and form an appropriate motor response in the absence of brain input. The spinal cord originates roughly at the level of your neck and runs down to the small of your back, giving it a length around 44 cm (17.5 inches). The diameter of the spinal cord is not uniform all the way down, being ~13 mm (0.5 inches) at its widest and ~6.5 mm (0.25 inches) in diameter at the thinner areas (slightly smaller than the diameter of a pencil.)

The spinal cord is housed within a series of bones, called the **vertebral column**. Although the

spinal cord itself is continuous, it can be divided based on the overlying vertebrae. A combination of a letter and a number is used to identify each section of the spinal cord, the letter corresponding to the vertebral section and the number referring to the number of bones down from the previous section (the smaller numbers are more anterior, larger numbers more posterior). Branching off from each section of the spinal cord are two pairs of nerves, the afferent (incoming to the CNS) sensory nerve roots which branch from the dorsal side of the spinal cord, and the efferent (outgoing from the CNS) motor nerve roots which branch from the ventral side of the spinal cord. These two branches meet and extend away from the spinal

**Figure 2.9** Unlike other mammals like dogs or cats, humans walk upright, giving us a “hooked” nervous system.



cord. After merging, they are called the **spinal nerves**, and humans have 31 pairs of these.

Moving from anterior (top) to posterior (bottom), the four regions of the spinal cord are:

### 1. Cervical

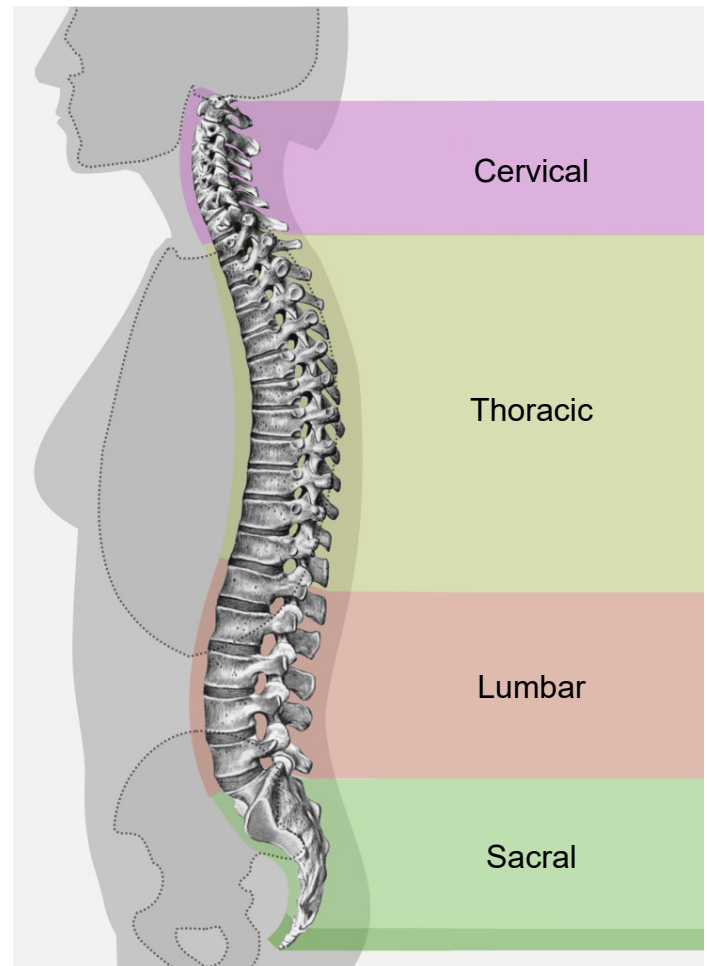
The cervical region corresponds to the upper 8 pairs of spinal nerves. Nerves that exit through the cervical region innervate the muscles in the neck, shoulders, arms and hands. Afferent nerves detect somatosensory inputs from these same areas. Sections C3 through C5 innervate the diaphragm, so an injury at this level or higher can quickly lead to death since the person may stop breathing. The spinal cord is at the widest diameter at the cervical area, as it has a swelling that corresponds to the many inputs and outputs to the arms.

### 2. Thoracic

There are 12 pairs of spinal nerves that make up the thoracic area of the spinal cord. These regions innervate the middle trunk area, the intercostal muscles between the ribs, and abdominal muscles. Branches off the spinal nerves in the thoracic areas are responsible for changing the activity of the various internal organs during a fight-or-flight response (more on the autonomic nervous system in section 2.2).

### 3. Lumbar

There are 5 pairs of lumbar spinal nerves. These pathways carry motor command information to the hips, thighs, and knees. Afferent lumbar inputs detect sensory information from the ventral side of the legs, such as the top of the thigh or the shin bone. As in the cervical region, the lumbar region has a swelling that increases the diameter of this section of spinal cord compared to the thoracic or sacral areas.

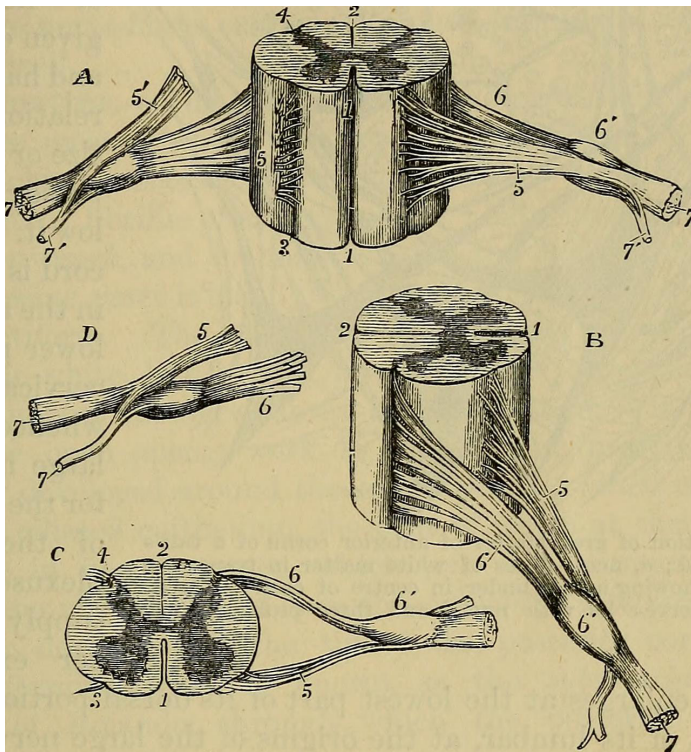


**Figure 2.10** The names of the regions of the vertebral column, the bones that protect the spinal cord.

### 4. Sacral

At the posterior-most end of the spinal cord is the sacral region, which consists of 5 pairs of nerves. Sacral spinal nerves control flexing of the toes. These nerves detect sensory information around the genital organs and the dorsal aspects of the legs, like the buttocks and the back of the thighs. There are also parasympathetic nerves that come from the sacral region, and these innervate the colon, bladder, and genital organs (again, more on the autonomic nervous system in 2.2).

Since information must pass through the anterior regions of the spinal cord to reach the



**Figure 2.11** Drawing of the spinal cord and the connecting spinal nerves.

posterior parts of the body, the more anterior an injury, the more parts of the body that are affected. The disease that affected former U.S. President Franklin Delano Roosevelt likely damaged posterior spinal cord structures, which explains why function of his legs was lost while function of his arms were left intact. However, the injury actor Christopher Reeves sustained while horseback riding destroyed his spinal cord at the anterior-most level of C1, causing complete paralysis and lack of sensation from the neck down.

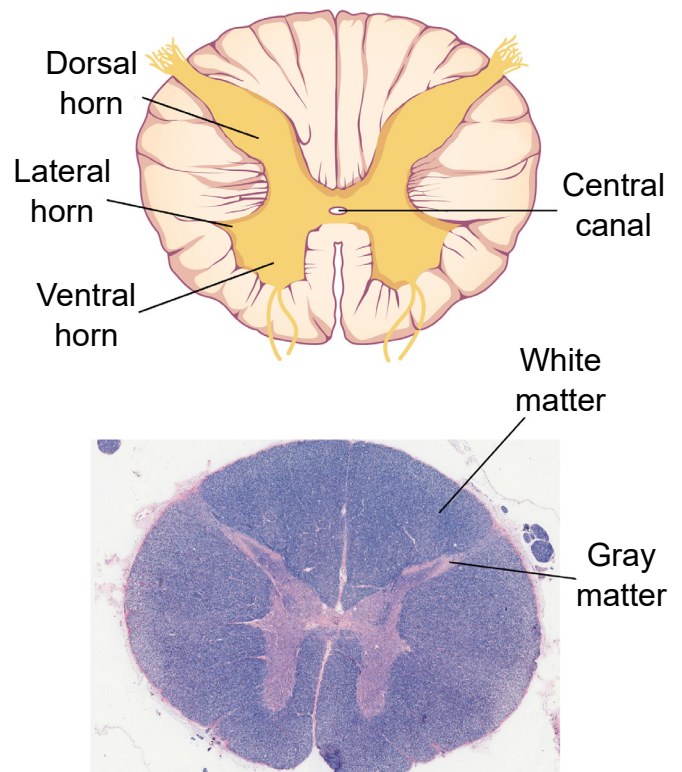
Unlike in the brain, there is basically only one truly meaningful projection of the spinal cord, and that is by cutting sections in the **transverse** plane. These sections are parallel to the ground if the spinal cord was oriented vertically, like a person standing up. Sometimes, this projection is also called a **cross-section**.

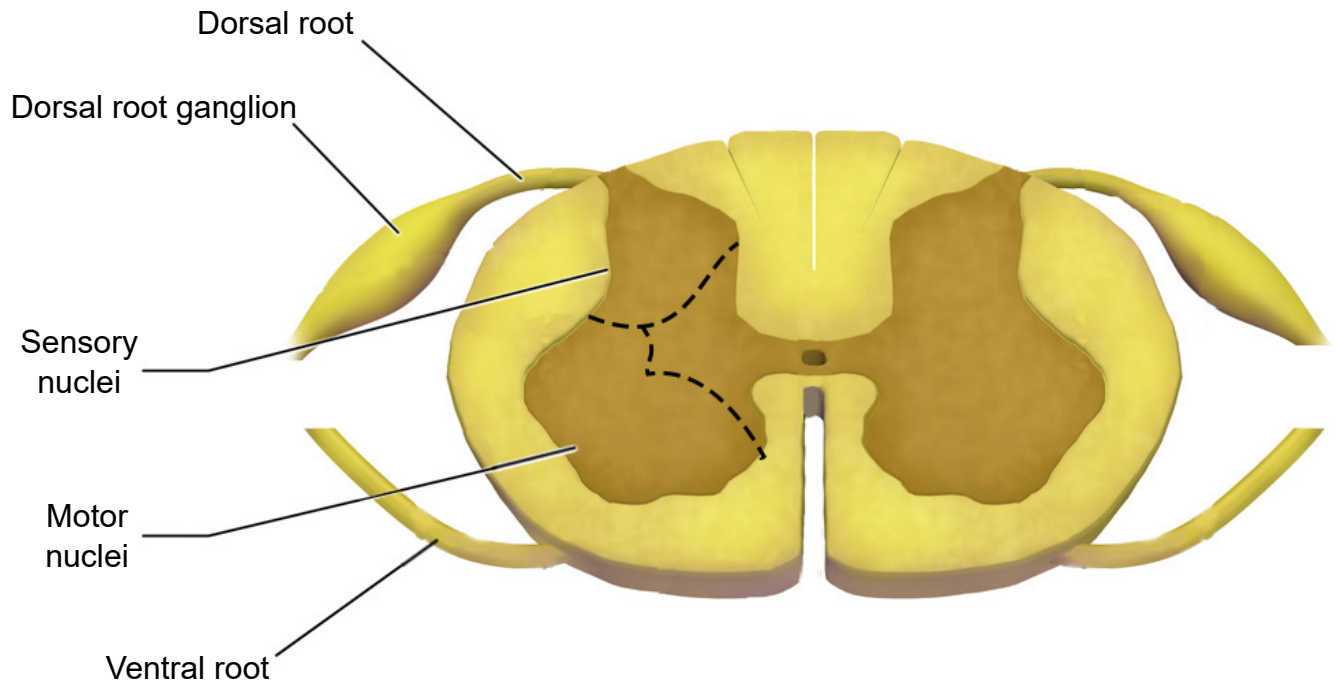
No matter which level of the spinal cord you look at, all cross-sections have a few

similarities. Most notably, the inner portion of a section has a butterfly-shaped structure of gray matter surrounded by a border of white matter. Gray matter contains mostly cell bodies while white matter contains mostly pathways of communication. Therefore, the ascending sensory tracts and descending motor tracts run along the outer portions of a spinal cord section.

Another feature that is seen across all levels of the spinal cord are the entry points for the afferent sensory nerves and the exit points for the efferent motor nerves. Somatosensory information arrives into the spinal cord from the dorsal side. Most of the sensory neurons have their cell bodies outside of the spinal cord in a large clump of nervous tissue close to the dorsal

**Figure 2.12** Cross-section (transverse) of the spinal cord showing a few anatomical features (top). Section of spinal cord stained with LFB, which dyes myelin in blue, which is why white matter looks more blue than gray matter (bottom).





---

**Figure 2.13** Cross-section of the spinal cord showing the dorsal root ganglion, the clump of cell bodies from the incoming sensory neurons.

---

side called the **dorsal root ganglion**. On the other hand, efferent motor nerves exit the spinal cord on the ventral side.

One of the main differences across different sections of the spinal cord is the ratio of white matter to gray matter. In general, the ratio leans towards more white matter at the anterior regions of the spinal cord compared to the posterior parts of the spinal cord.

The CNS ends at the spinal nerves. The remaining nerves that affect the muscles and beyond are the beginning of the peripheral nervous system.

---

## 2.2 Peripheral nervous system (PNS)

---

The PNS functions as the intermediary between the CNS and the rest of the body, including the skin, internal organs, and muscles of our limbs.

When talking about the PNS, another pair of anatomical words will be introduced, **proximal** and **distal**. A part of the body that is more proximal is something that is in close *proximity* to the CNS, whereas something that is distal is farther away, or more *distant*, from the CNS. For example, the efferent nerves that project to the neck and

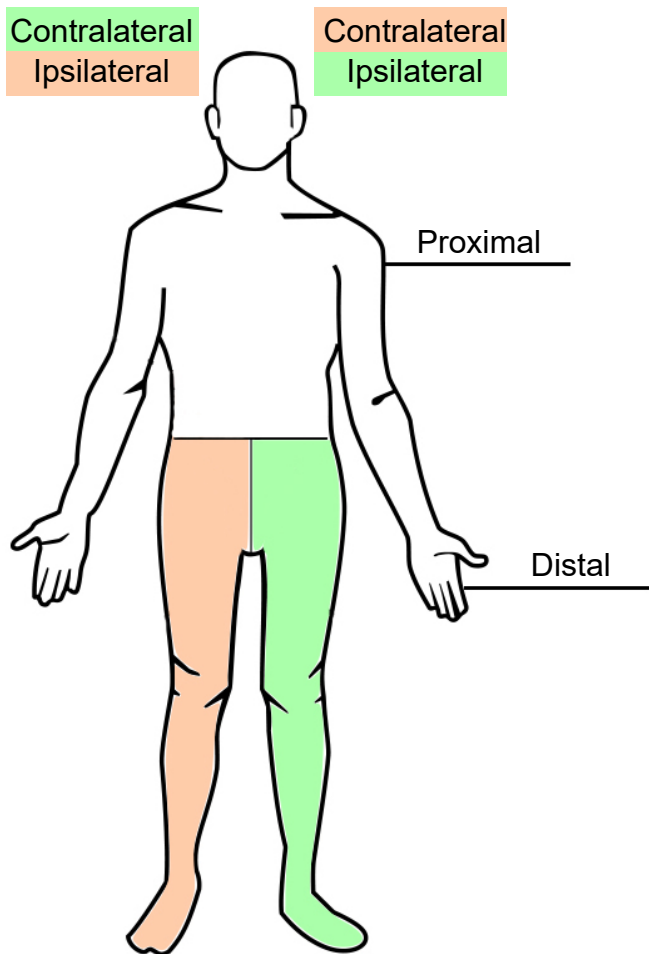
shoulder muscles are proximal to the nerves that project to the hand muscles.

Another pair of anatomical terms that is useful in describing the nervous system is **contralateral** and **ipsilateral**. When the vertebrate nervous system evolved, there was a preference for a “crossed system,” one where the left half of the brain generally controlled and received information from the right half of the body, and vice versa. This type of communication is called a contralateral connection. Most parts of the nervous system have this contralateral organization, where stuff on the left side of our vision first goes into the primary visual cortex of the right brain, physical sensations on the left hand first goes into the somatosensory cortex of the right brain, and so on. The opposite of contralateral is ipsilateral, and you would use this word to describe a part of the body that is on the same side as that half of the nervous system. For example, the right hand is ipsilateral to the right hemisphere of the spinal cord.

The PNS can be divided into three main branches:

### 1. Somatic nervous system

The somatic nervous system represents all the parts of the PNS that are involved with the outside environment, either in sensing the environment or acting on it. For example, the nerves that detect pressure or pain on the foot are part of the afferent somatic nervous system. We also think of the PNS as the branch that sends signals to our skeletal muscles. The nerves that innervate the muscles of the legs as we run are part of the efferent somatic nervous system. The somatic nervous system is also called the



---

**Figure 2.14** Anatomical language used in describing relationships from parts of the nervous system.

---

“voluntary nervous system” since it is used to cause muscle movement related to intentional actions.

## 2. Autonomic nervous system

The autonomic nervous system encompasses all the branches of the PNS that deal with the internal environment. As with the somatic nervous system, the autonomic nervous system is comprised of nerves that detect the internal state as well as nerves that influence the internal organs. The body carries out all sorts of functions and responses unconsciously without any intentional control. It can do so by sending signals to smooth muscles and glands. The signals that cause us to sweat when it is hot, our pupils to dilate when it is dark, and our blood pressure to adjust when we stand up too quickly are all driven by the nerves of the autonomic nervous system.

Imagine what would happen to your body if you, while walking through the quad, turned a corner and encountered a huge feral tiger, somehow set free from the Lincoln Park Zoo. You would notice a sudden fear response: your heart rate would skyrocket, you would start breathing more rapidly, and your body temperature might increase. Furthermore, your body will undergo additional reflexive responses that you might not even notice: your pupils will dilate, the bronchioles in your lungs will dilate, and your liver and kidneys will start to activate a variety of enzymes. All of these responses happen within seconds of seeing the tiger.

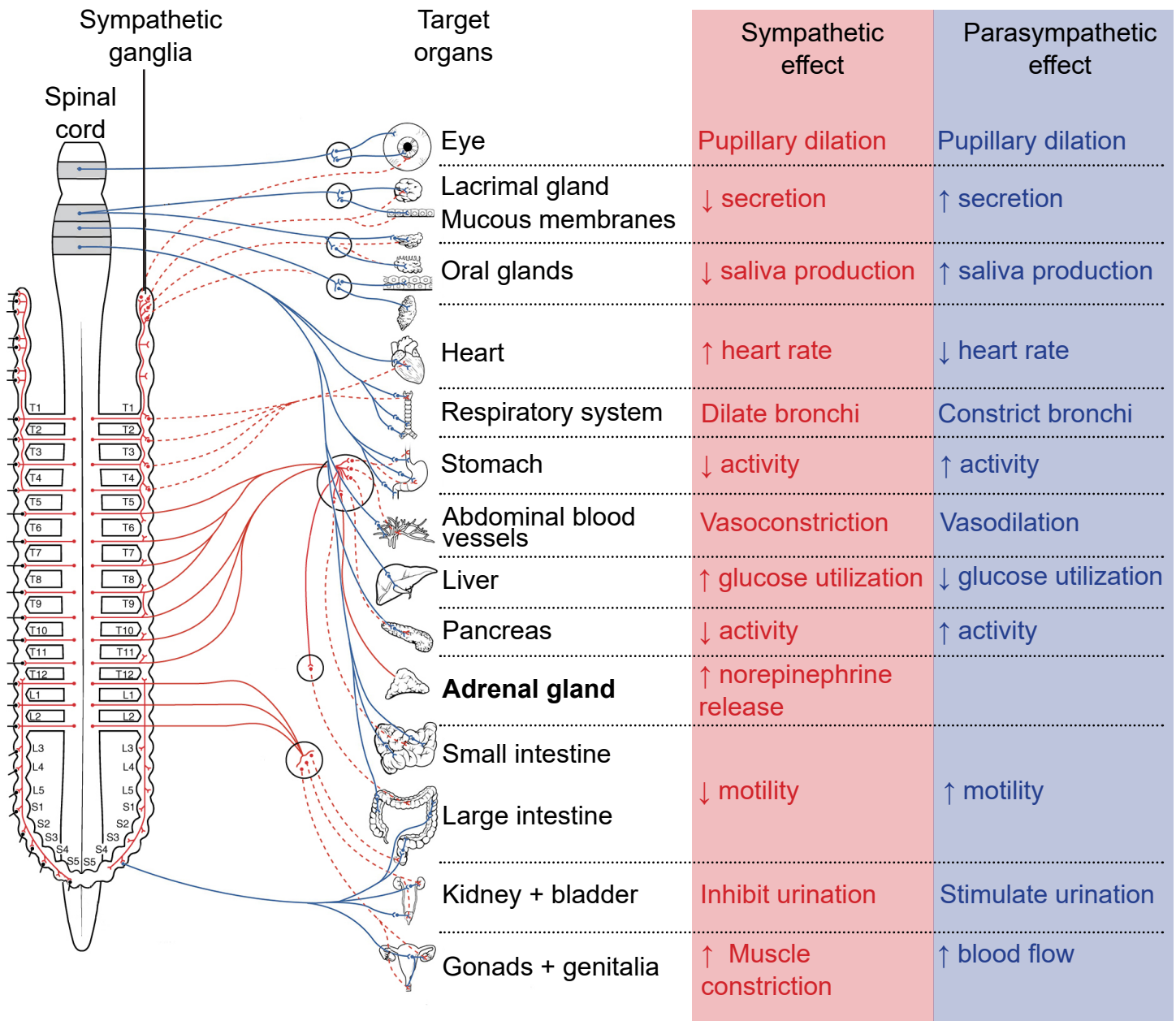
This set of physiological changes to a threat is sometimes called the **fight-or-flight response**, which is driven by one of the two branches of the autonomic nervous system, the **sympathetic nervous system**. The sympathetic nervous system activates when we are faced with

a threat, either perceived or real. All of these rapid bodily responses result in the body preparing to attack or defend itself. Increased respiration allows the body to take in more oxygen, and dilation of blood vessels in the muscles allows that oxygen to get to the muscles, which is needed for muscle activation.

Now, consider a completely opposite scenario. You’ve just gorged yourself on a huge dinner of deep dish pizza, Italian beef sandwiches, bacon cheese fries, and tiramisu for dessert. You would probably feel relaxed, satisfied, and more than a little sluggish. A different physiological response is happening, a behavior called the **rest-and-digest** response. These physiological changes are driven by the other main branch of the autonomic nervous system, called the **parasympathetic nervous system**.

Both the sympathetic nervous system and parasympathetic nervous systems influence the internal organs simultaneously. At all times, the heart is getting signals from the sympathetic nervous system which increase heart rate, and signals from the parasympathetic nervous system which decreases heart rate. However, this seesaw-like balance can shift quickly in either direction, such as inducing a sympathetic response if a fearful stimulus is encountered, like the runaway tiger.

The sympathetic and parasympathetic nervous systems differ anatomically as well. The nerves that drive the sympathetic response branch off the spinal cord at the thoracic and lumbar levels, so sometimes we can use thoracolumbar to describe the site of origin. The nerves form a chain of many clumps of cells that run alongside the spinal cord, called the **sympathetic ganglion**. On the other hand, parasympathetic drive originates predominantly in the cervical spinal cord, with some signals originating in



**Figure 2.15** Diagram showing innervation of different organs by the sympathetic and parasympathetic nervous systems and the corresponding effect. Note that the adrenal gland does not have parasympathetic activity.

the sacral areas. The parasympathetic nervous system usually receives signals from several cranial nerves. CN X, also called the **vagus nerve** innervates multiple bodily organs in the midsection of the body (vagus comes from the same root word as *vagrant*, appropriate since this nerve wanders all around the body.)

### 3. Enteric nervous system

The internal organs that carry out digestive functions, such as the esophagus, stomach, and intestines, are surrounded by a dense mesh of neurons that regulate their activity. Consisting of half a billion nerve cells, this net of neurons cause the digestive tract to increase or decrease the rate of these processes depending on the body's demands.



The enteric nervous system receives signals from both the sympathetic and parasympathetic nervous systems, and functions without our conscious knowledge. Historically, these digestive functions have been classified as part of the autonomic nervous system, but these responses do not share the same reflex pathway, and the enteric signals can work entirely independent of the vagus nerve, for example.

## Cranial nerves

Many sensory and motor nerves originate in the spinal cord, but there are 12 pairs of nerves that exit from the brain. These **cranial nerves** can control motor functions, carry out general or specialized sensory functions, or both. The cranial nerves usually deal with parts related to the head, but not exclusively.

**Table 2.16** The twelve cranial nerves and their function.

Cranial Nerve	Function	Description
CN I Olfactory nerve	Sensory	Sense of smell
CN II Optic nerve	Sensory	Sense of vision
CN III Oculomotor nerve	Motor	Control of extraocular muscles which allow movement of eyeballs; constriction of pupils; changing of lens shape
CN IV Trochlear nerve	Motor	Control of the superior oblique muscle of the eye that moves the eyeball down and lateral
CN V Trigeminal nerve	Sensory + motor	Tactile and pain sensory information from the face and mouth; Control of muscles used in chewing
CN VI Abducens nerve	Motor	Control of the lateral rectus muscle of the eye that moves the eyeball outward laterally
CN VII Facial nerve	Sensory + motor	Control of the muscles that allow for facial expressions; Taste sensation on the anterior 2/3rds of the tongue
CN VIII Vestibulocochlear nerve	Sensory	Detection of sound information and head positional (vestibular) information
CN IX Glossopharyngeal nerve	Sensory + motor	Detection of somatic sensory in the middle ear and posterior 1/3rd of the tongue; Taste sensation on the posterior 1/3rd of the tongue; Controls the stylopharyngeal muscle that allows swallowing;
CN X Vagus nerve	Sensory + motor	Control of the internal organs by autonomic nervous system using parasympathetic activity
CN XI Accessory nerve	Motor	Control of the sternocleidomastoid and trapezius muscles of the neck and shoulders
CN XII Hypoglossal nerve	Motor	Control of the muscles of the tongue

---

## 2.3 Support structures of the nervous system

---

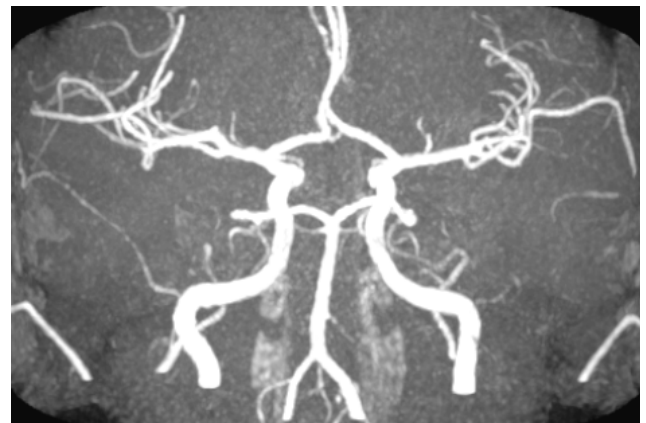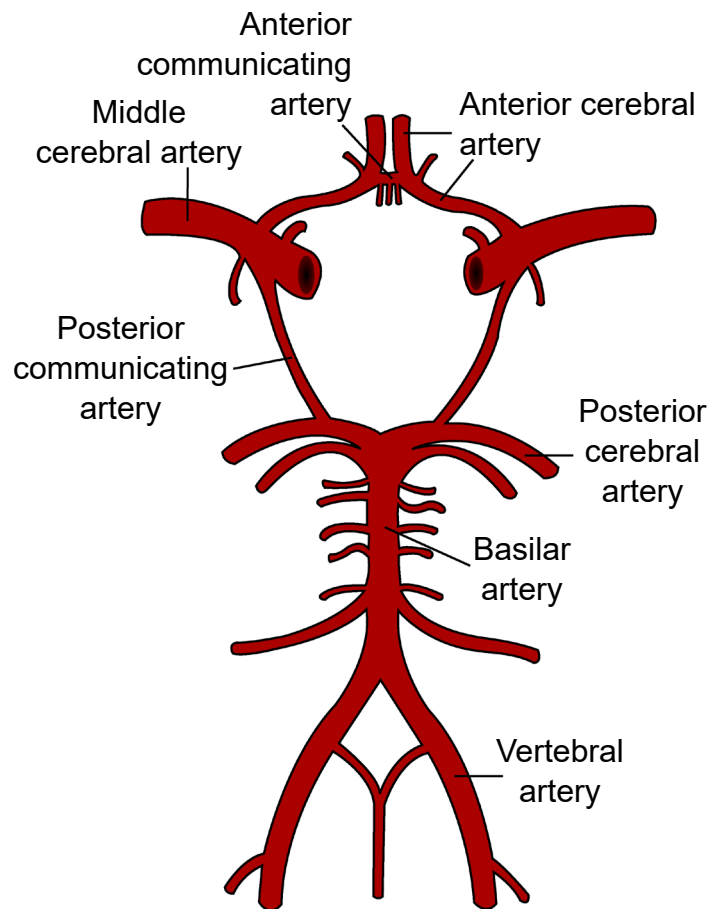
Although we mostly think about nerve cells as being the main characters of the nervous system, there are many other anatomical features that play important supporting roles. These are often

non-neuronal structures, but are still critically important in allowing the nervous system to do what it needs to do.

### Brain circulation and cerebral blood flow

Like every other organ in the body, the brain requires oxygen and nutrients to function. In humans, this function is accomplished by the blood that is pumped around the body using a network of blood vessels called the circulatory system. The brain has a very high demand for oxygen and nutrients: at only 2% of total body weight, it receives about 15% of total cardiac output.

Oxygenated blood moves anteriorly through the aorta into the brain via two different pairs of arteries, the vertebral arteries and the internal carotid arteries. The left and right vertebral arteries merge into a single basilar artery, and along with the left and right internal carotid arteries, feed into a loop-like circular blood vessel called the **circle of Willis**. According to one theory, the circle of Willis is an anatomical redundancy that allows an organism to maintain cerebral blood flow even if one part of the arterial system is narrowed or blocked. From here, the circle of Willis has paired “exit” arteries that distribute blood to different areas of the brain: the **anterior cerebral arteries** provide blood to dorsomedial cortical structures and deep brain structures, and the **posterior cerebral arteries** provide blood to the occipital lobe. The other major arteries are called the **middle cerebral arteries** which branch off the internal carotid artery and deliver blood to the lateral cortices.



**Figure 2.17** Diagram of the circle of Willis (top) and an angiogram (bottom) showing the structure in real life.

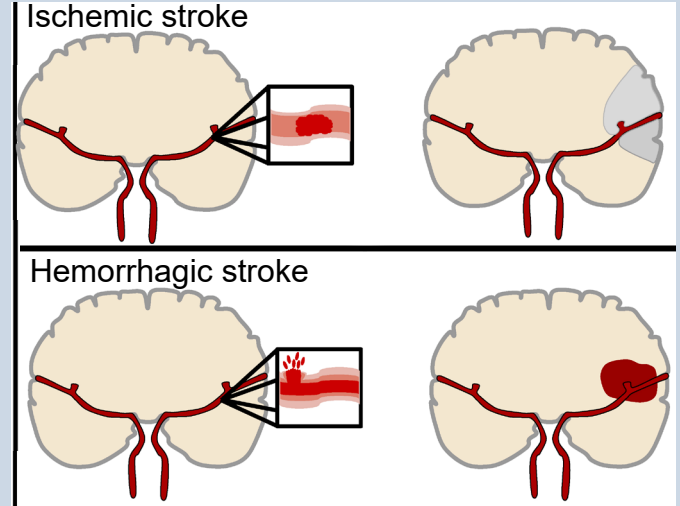
### Clinical connection: Stroke

Stroke is an extremely common, life-threatening medical condition that results in a loss of blood flow to the brain. According to 2016 statistics from the World Health Organization, stroke is the second highest cause of death worldwide. The number one risk factor for stroke is high blood pressure.

There are two common types of strokes that a person may experience. More than 80% of all strokes are **ischemic strokes** (pronounced *is-keemik*), which happens when normal blood flow is interrupted, causing cell death by deprivation of brain tissue of oxygen and nutrients. Generally, this type of injury can happen when a blood clot forms, travels through the circulatory system and gets lodged in a tiny brain blood vessel, thus blocking the passage of blood.

The other 20% of strokes are **hemorrhagic strokes**, which results from a burst blood vessel that causes bleeding into the brain. The presence of uncontrolled blood inside the brain causes an increase in intracranial pressure, which can be lethal. Many brain cells may die since they cannot take up oxygen directly from the blood. Additionally, blood has dramatically different properties than the normal solution which the brain cells live in, and this can cause the neurons to trigger a self-destruction program. Generally, hemorrhagic stroke is more deadly than ischemic stroke.

Because the different blood vessels of the brain's circulatory system are responsible



**Figure 2.18** Diagram illustrating the two main types of stroke and the effect on blood flow to the brain

for providing blood to specific areas of the brain, it is possible to diagnose the specific area where the stroke is happening based on the presentation of symptoms. For example, if the middle cerebral artery blood is occluded by an ischemic stroke, the left hemisphere motor cortex will lose blood flow. Because of the contralateral organization of the descending motor pathway, the patient may therefore present with paralysis or weakness in the right half of the body.

It is vitally important to correctly diagnose and differentiate between the two types of strokes. An ischemic stroke may be treated with injection of a “clot-busting” drug, a substance that helps the body break down the offending blockage. However, these clot-busters could make the bleeding from a hemorrhagic stroke even worse.

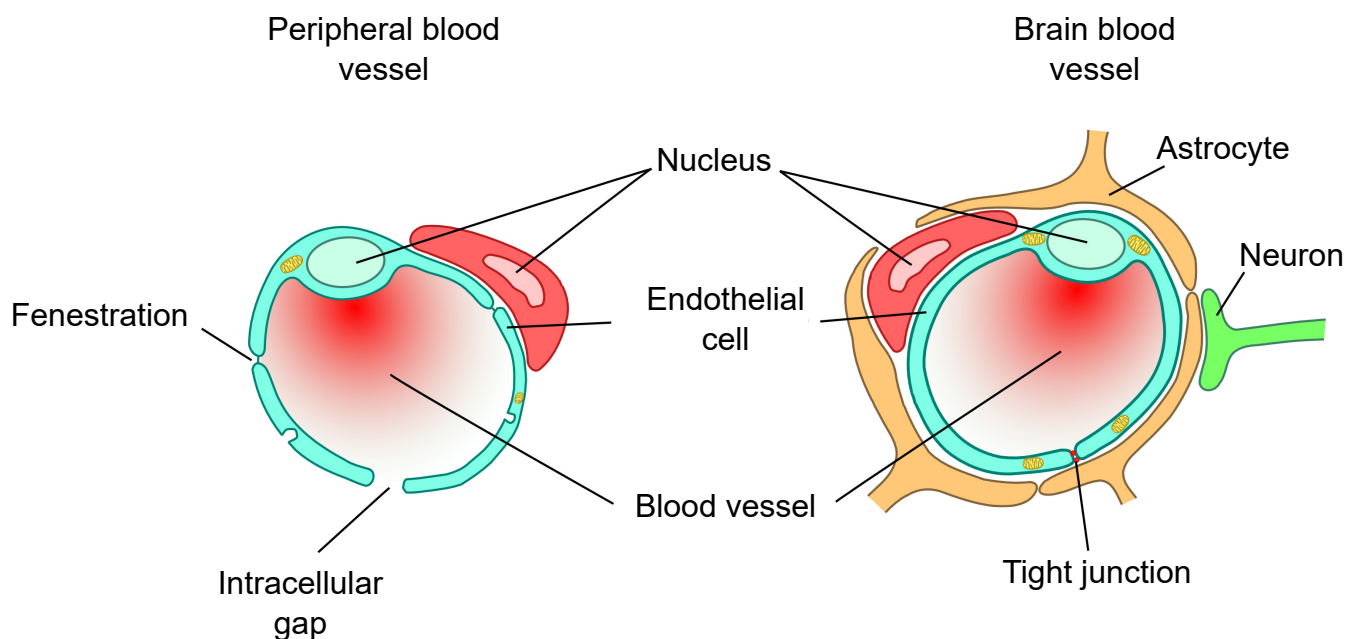
## Blood-brain barrier (BBB)

It is important for oxygen and nutrients to pass from the blood into the brain tissue. Small blood vessels outside of the brain, such as the capillaries in the fingertips, have very thin walls, sometimes the width of a single cell, and are therefore highly permeable to gases. These vessels can either contain tiny holes or large protein structures that physically transport substances across the blood vessel. On the other hand, it is also advantageous to separate toxins and foreign pathogens in the bloodstream from getting into brain tissue. The **blood-brain barrier (BBB)** is an anatomical adaptation that selectively transports substances necessary for normal biological function, while simultaneously excluding potentially harmful invaders from the brain. The BBB physically surrounds blood vessels in the brain. It is made up of endothelial cells and a type of glial cell called an **astrocyte**. The BBB is injured in all variety of medical disorders, ranging

from stroke, epilepsy, and Alzheimer's disease, just to name a few. It is still unknown what role the disruption of the BBB plays in brain disorders.

The exclusive nature of the BBB can be a double-edged sword. It is difficult to deliver a drug into the brain from the blood stream if that drug is unable to pass through the BBB. For example, the current gold standard pharmaceutical treatment for Parkinson's disease is to increase the brain's levels of dopamine. However, dopamine does not pass through the BBB. To get around this, physicians give the BBB-permeable substance L-DOPA, which the brain is able to convert into dopamine. Many other therapeutic drugs do not cross the BBB, so researchers are developing methods using electromagnetic fields to temporarily weaken the barrier, or surround the drugs in nanoparticles, which are so small that the body cannot identify as foreign.

**Figure 2.19** The blood-brain barrier separates blood vessels from the brain tissue. Peripheral blood vessels do not have such an anatomical adaptation.



## The ventricles and cerebrospinal fluid (CSF)

In a coronal section of the brain, it is very common to see large symmetrical “holes” near the medial aspect. These spaces are called **ventricles**. The human brain has a total of four ventricles in the brain. The two very large paired ventricles, one in each hemisphere, are the **lateral ventricles**. They are connected medially into the **third ventricle**, which extends to the posterior aspect of the brain. From here, an aqueduct that runs ventrally extends into the **fourth ventricle** before continuing into the **central canal**, a narrow space that runs all the way through the length of the spinal cord along the midline. The entire ventricular system is entirely connected.

The ventricles are filled with a liquid called **cerebrospinal fluid (CSF)**. CSF is basically a high salt water solution (sodium ions at 140 mM and chloride ions at 110 mM). Because of the high osmolarity of CSF, it is a very buoyant solution. Like a fully grown person who can float easily on the surface of the extremely salty Dead Sea, CSF allows the brain to remain “floating”

inside the skull. Without CSF, the brain weighs almost 1.5 kg (~3 lbs). Cells and blood vessels at the ventral base of the brain would be crushed under the weight of the brain itself. But when the brain is surrounded by CSF, it weighs less than 50 grams, almost two orders of magnitude lighter!

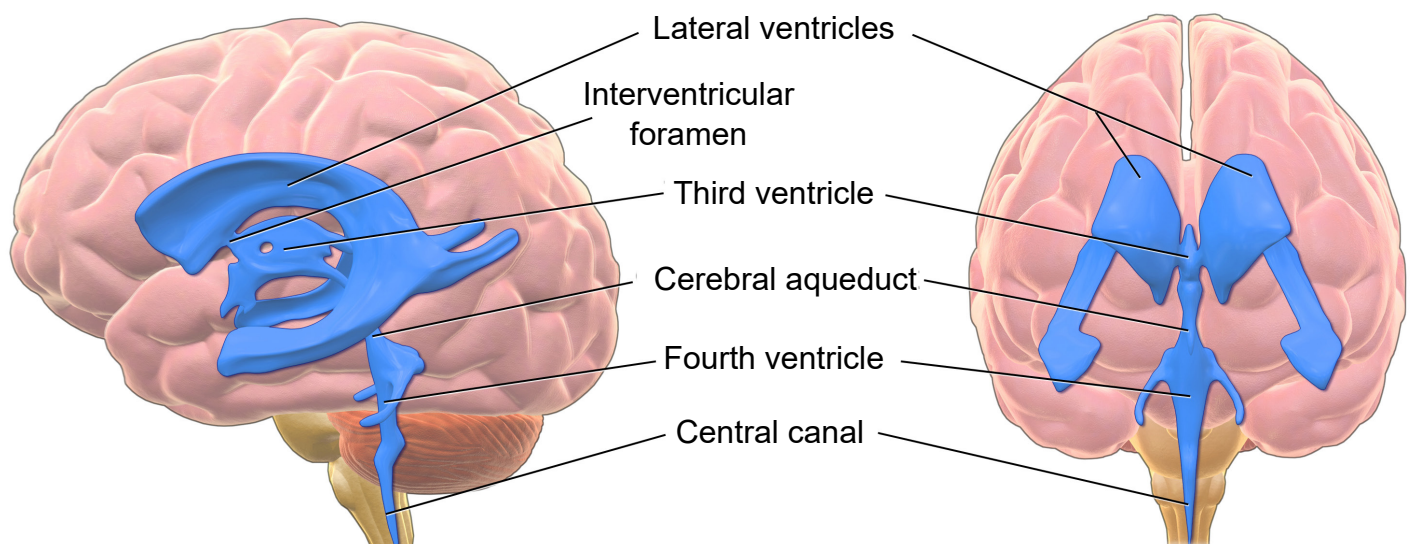
CSF is also found in a tightly-regulated membranous sac called the **meninges** (more about it below) that encases the brain. In fact, more than 80% of the CSF in the body exists in this space outside the brain. This liquid serves as a form of “cushioning” that protects the brain from rapid head movements. If it weren’t for this physical protection, the inertia of head movement may cause your brain to smash against the inside of the rigid skull if you move your head too quickly. The CSF layer allows the head to withstand some sloshing of the brain, but a movement that is too abrupt can cause a traumatic brain injury, a condition that we will return to in chapter 15.

CSF can also function as a way to wash impurities out of the brain. The volume of CSF in

---

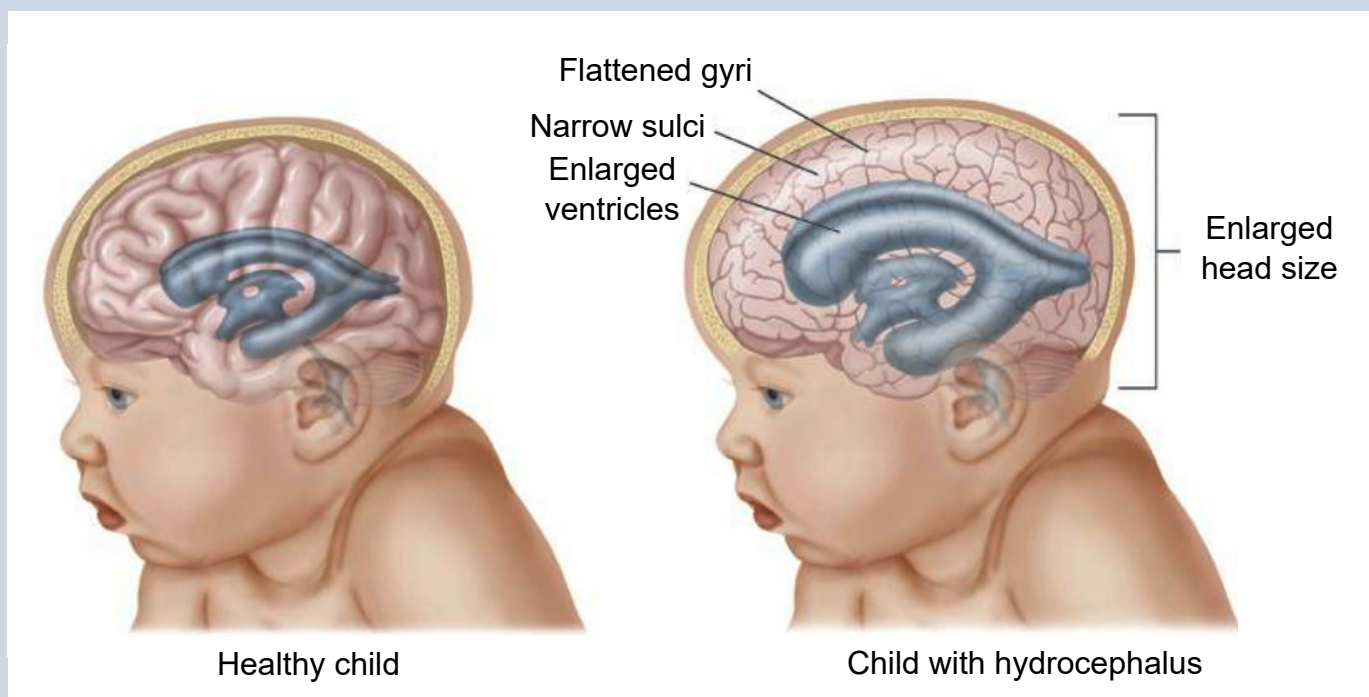
**Figure 2.20** The ventricular system consists of several interconnected chambers filled with cerebrospinal fluid (CSF).

---



## Clinical correlation: Hydrocephalus

A common condition affecting the brain of about 1 in 200 newborns and a small number of adults is hydrocephalus, historically called “water on the brain.” In patients with hydrocephalus, the volume of CSF increases, which elevates intracranial pressure, causing symptoms such as fever, stiff neck, headache, seizures, or altered mental status. In adults, the skull is rigid and unmoving. But in newborns with hydrocephalus, the plates of the skull are not completely fused together. Often, these children will have a bulging parts on the skull and an expansion of the forehead. Increased CSF volume can happen in a couple ways. The clearance of CSF may fail while production remains normal, or the entrance to the central canal in the spinal cord may be narrowed or blocked by a tumor, leading to an increase in the volume in the brain. A common treatment for hydrocephalus is to surgically implant a shunt, which is a hollow tube that runs from the ventricle down into the abdominal space, which allows for drainage thus decreasing intracranial pressure.



**Figure 2.21** Hydrocephalus is one of the most common birth defects, affecting around 0.1% of births in the United States. It can also affect adults. Hydrocephalus can be deadly.

the typical human body is about 150 mLs, a little more than half a cup. Because there is frequent turnover of CSF, the material gets absorbed back into the body regularly. Each day, the body produces about half a liter of CSF, so the brain cycles through the entire volume a few times

each day. Since the CSF is in close association with the neurons, cellular waste materials get dissolved into CSF, which can then be degraded and broken down outside of the brain.

# Meninges

The brain is a squishy internal organ housed inside the skull. If there weren't some protective buffer separating the soft brain matter from the rigid bone, the jelly-like brain would be smashed up against the inside of the skull and get injured as the head moves around. The meninges are a series of protective membranes that minimize this kind of damage. They surround the brain and extend all the way down the spinal cord. Think of the meninges as an organic type of "bubble wrap" that encases a fragile nervous system.

There are three types of membranes that collectively make up the meninges. From the outside-most layer to the innermost, they are:

**1. Dura mater.** The dura is made of thick, fibrous material, and can get to be 0.8 mm thick in

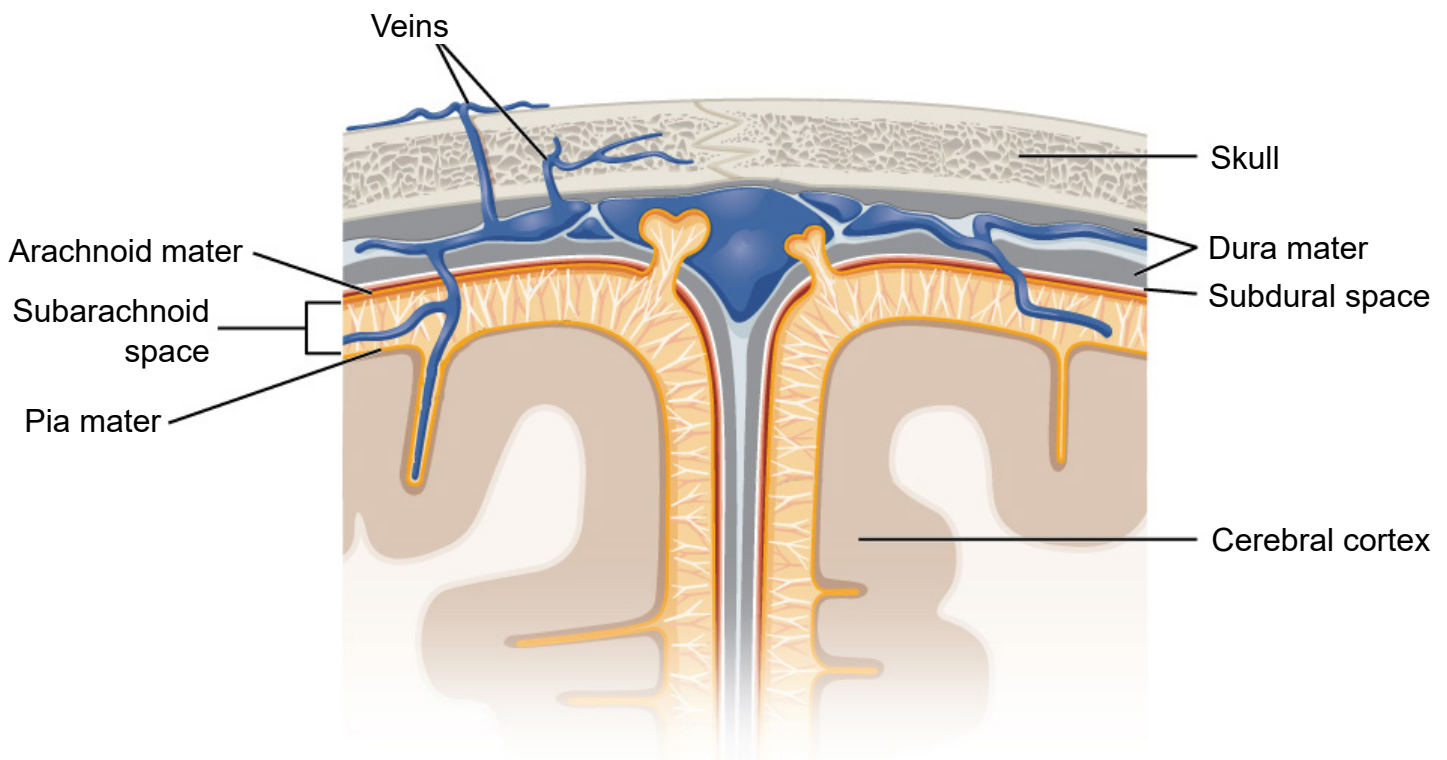
the adult body (if you took a piece of printer paper and fold it in half four times, that should give you an idea of how thick the dura mater is in the adult human). The dura mater is physically attached to the inside of the skull with highly resilient connections found at the sutures between the plates of the cranium. The name originates from Latin meaning *tough mother*.

**2. Arachnoid mater.** The arachnoid mater is the middle layer of the meninges. The fibers are very delicate and resemble a spider web, which is where the name comes from. Within this space, there are protrusions that allow for CSF to drain into sinuses, which allow for recycling of soluble substances. Most of the CSF in the brain exists underneath this layer in the *subarachnoid space*.

---

**Figure 2.22** The meninges are a series of protective membranes that surround the CNS.

---



**3. Pia mater.** The pia mater is the third layer of the meninges. It is very fragile and in direct contact with the surface of the brain, and closely follows the sulci and gyri. The name means pious mother.

#### **Clinical correlation: Meningitis**

Inflammation of the meninges is a potentially deadly condition called meningitis. Exposure to infectious agents like viruses or bacteria such as *Neisseria meningitidis* that leaks from the blood into the meninges is a common cause of the inflammation. When the meninges are inflamed, the brain gets compressed from all sides, increasing intracranial pressure, producing many of the same symptoms seen in hydrocephalus: fever, stiff neck, headache, seizures, and altered mental status. The *N. meningitidis* bacteria and the viruses are highly transmissible in close contact, but vaccinations are highly effective at minimizing the infection rate. As with bacterial infections, broad-spectrum antibiotics are effective at treating the infection.